

Endobronchial recurrence of non-Hodgkin's lymphoma mimicking foreign body aspiration

AHMET AKÇA^{1,*}, MERİBAN KARADOĞAN², DEMİR KÜRŞAT YILDIZ³,
FUNDA ÇORAPÇIOĞLU², YONCA ANIK⁴

¹Department of Radiology, Dr. Lutfi Kırdar Kartal Education and Research Hospital, Istanbul, Turkey

²Department of Pediatric Oncology, Kocaeli University School of medicine, Kocaeli, Turkey

³Department of Pathology, Kocaeli University School of Medicine, Kocaeli, Turkey

⁴Department of Radiology, Kocaeli University School of Medicine, Kocaeli, Turkey

*Corresponding author: Ahmet Akça; Department of Radiology, Dr. Lutfi Kırdar Kartal Education and Research Hospital, Istanbul, Turkey; E-mail: one_442@yahoo.com

(Received: November 4, 2014; Revised manuscript received: March 13, 2015; Accepted: May 18, 2015)

Abstract: A 2-year-old patient with a history of non-Hodgkin's lymphoma (NHL) was presented to our hospital with the complaint of shortness of breath and wheezing. Posteroanterior chest radiograph revealed hyperlucency and hyperexpansion of the right hemithorax. We performed computed tomography (CT) because of a suspicion of foreign body aspiration. CT revealed right main bronchus occlusion by a hypodense lesion. Bronchoscopy revealed a mass lesion in the right main bronchus which was histopathologically diagnosed as NHL. Only a few cases of endobronchial recurrence of lymphoma have been reported in the current literature, but there is no reported case in a pediatric patient.

Keywords: non-Hodgkin's lymphoma, lymphoma, endobronchial lymphoma, foreign body aspiration, wheezing, bronchus occlusion, bronchoscopy

Introduction

Non-Hodgkin's lymphoma (NHL) involves intrathoracic structures in about 43% of cases at some stage in the course of disease [1]. The observations suggest that endobronchial involvement is extremely rare in patients with NHL [1] and usually occurs in the presence of disseminated disease [2]. The possible mechanisms of endobronchial involvement of malignant lymphoma are: arise in a bronchus-associated lymphoid tissue, directed bronchial invasion, and lymphatic spread [3]. When NHL involves the bronchial tree, it should be differentiated from bronchial adenoma or primary bronchogenic carcinoma [4]. In this case, we aimed to present a rare case of endobronchial lymphoma mimicking foreign body aspiration. Because our patient is 2-years old and the clinical-radiological findings were compatible with foreign body aspiration, we performed bronchoscopy and the patient was histopathologically diagnosed as endobronchial lymphoma.

Case Report

A 2-year-old female was admitted to our hospital with the complaint of right-sided neck swelling and cough lasting for 10 days, in September 2011. Parents informed us that she had night sweat and 2 kg loss in weight over 10 days. Laboratory tests revealed no abnormality. Physical examination revealed palpable masses in the right neck and submandibular region. The patient was then referred to the radiology department for diagnostic imaging. A neck, thorax, and abdominal computed tomography was performed before and after contrast administration, using a Toshiba Aquilion 64-slice scanner. Computed tomography (CT) of the neck showed lymphadenopathies in the right submandibular region and in the right posterior cervical chain, 4 cm in maximum diameter. Thorax CT showed bilateral lung nodules and subcarinal and bilateral hilar lymphadenopathies. Abdominal CT revealed hypodense lesions in the liver which were solid on ultrasonography. Excisional cervi-

cal lymph node biopsy was performed. Pathologic examination revealed MUM-1 (+), CD10 (-), Bcl-6 (-), and CD79a (+) cells in marginal and paracortical zone. The immunophenotype was consistent with diffuse large B-cell lymphoma (DLBCL). Thus, the patient was diagnosed as DLBCL.

After receiving chemotherapy according to NHL-BFM-95 protocol (non-Hodgkin's lymphoma-Berlin-Frankfurt-Münster-95) between November 2011 and May 2012, complete response was achieved and she was free of complaints until February 2013. On february 2013, the patient presented at the emergency department with shortness of breath and wheezing. Posteroanterior chest radiograph revealed hyperlucency and hyperexpansion of the right hemithorax (*Fig. 1*). We performed CT because of a suspicion of foreign body aspiration. CT revealed right main bronchus occlusion by a hypodens lesion (*Fig. 2*) and hyperaeration of the right lung (*Fig. 3*). There was no abnormality in the neck and abdomen, and there was no B symptoms.

Laboratory examination revealed a white blood cell (WBC) of 11,100/mm³, hemoglobin of 14.2 g/dL, and lactate dehydrogenase (LDH) of 271 U/L. Clinical and radiological findings were compatible with foreign body aspiration, the patient underwent bronchoscopy. Bronchoscopy revealed a mass lesion in the right main bronchus but no foreign body. Biopsy of the lesion was performed which revealed diffuse large B-cell lymphoma. After pathologic diagnosis, positron emission tomography-computed tomography (PET-CT) was performed which revealed increased F-18 fluorodeoxyglucose (FDG) uptake in the region of right main bronchus (*Fig. 4*). We diagnosed the patient as endobronchial recurrence of NHL. The patient received 30 Gy radiotherapy and chemotherapy including ICE regimen (ifosfamid, carboplatin, etoposide) and rituximab. The patient underwent bone marrow transplantation after chemotherapy and radiotherapy and died after transplantation due to cytomegalovirus (CMV) pneumonia.

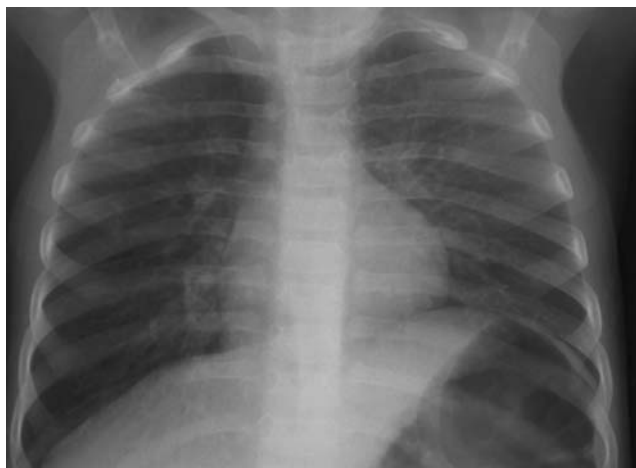

Fig. 1. Posteroanterior chest radiography shows the hyperlucency and hyperexpansion of the right hemithorax

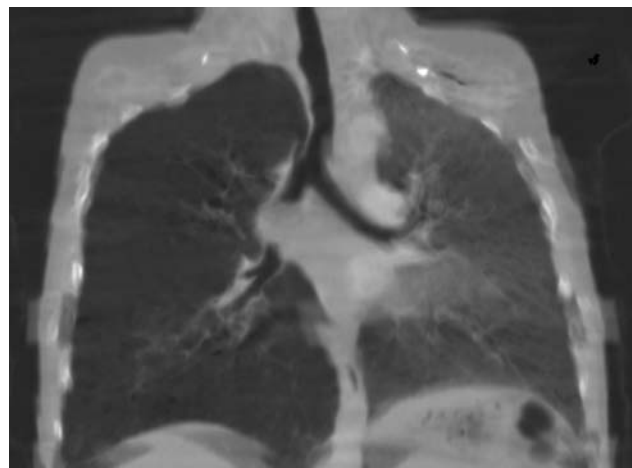


Fig. 2. Coronal reformat CT shows the right main bronchus occlusion by a hypodens lesion (arrow)

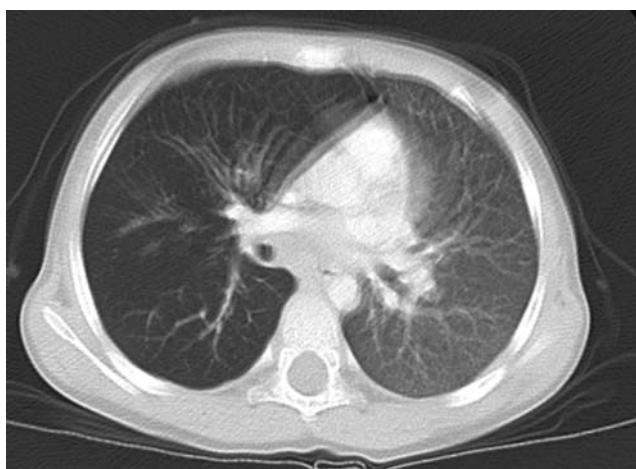

Fig. 3. Axial CT shows the hyperaeration of the right lung

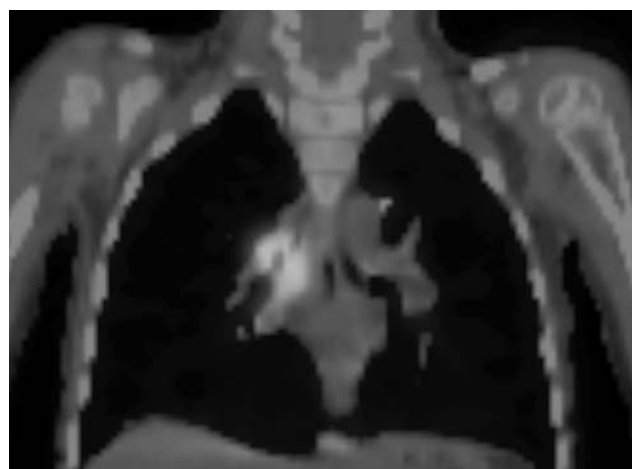


Fig. 4. PET-CT shows the increases FDG uptake in the region of right main bronchus

Discussion

Endobronchial masses usually arise from neoplastic spread from lung tumors and less frequently from distant metastases from tumors of the gastrointestinal tract, breast, kidney, skin, and reproductive organs. Endobronchial metastases from distant malignant tumors are found in 2% of autopsies in patients with cancer. Lymphomas involving the chest can involve lymph nodes, pulmonary parenchyma, or the tracheobronchial tree [5]. The observations suggest that endobronchial involvement is extremely rare in patients with NHL [1] and usually occurs in the presence of disseminated disease [2]. The involvement of tracheobronchial tree is more common in Hodgkin's lymphoma than in NHL [1]. The most common involvement is displacement or narrowing of airway lumen by enlarged mediastinal or hilar lymph nodes, followed by diffuse peribronchial infiltrates resembling lymphangitis carcinomatosa and as an endobronchial mass [1] as we see in our case.

There are different mechanisms postulated for the development of endobronchial lesions in lymphoma. These include direct invasion from adjacent mediastinal or parenchymal disease, lymphatic spread to peribronchial connective tissues, hematogenous spread [1], or transbronchial aspiration of tumor emboli [4]. However, the most common explanations for endobronchial NHL are direct bronchial invasion from mediastinal mass and lymphatic spread to peribronchial connective tissues [4]. Primary lesions also reported, but it is rare for an endobronchial lesion to be the primary presentation of lymphoma [5, 6].

Endobronchial NHL masses are always associated with airway obstruction [5]. Rose et al. [7] reported that two clinical-radiologic patterns of endobronchial involvement with NHL could be delineated. The most common pattern (Type 1) is characterized by the presence of diffuse submucosal nodules lining bronchoscopically visualized airways in individuals with clinically apparent systemic lymphoma. Type 2 is characterized by the presence of a localized endobronchial mass of NHL which was associated in all instances with signs of airway obstruction such as cough and wheeze.

The clinical importance of endobronchial malignancy lies in the capacity of these lesions to produce airway obstruction that is indistinguishable clinically and radiologically from bronchogenic carcinoma [7]. When

NHL involves the bronchial tree, it should be differentiated from bronchial adenoma or primary bronchogenic carcinoma [4]. Our case was indistinguishable clinically and radiologically from foreign body aspiration because of the patient's age, and because the patient had no B symptoms and no laboratory abnormality. In the majority of cases, the definitive diagnosis is suggested by finding evidence of the primary malignancy at another site [7] and confirmed by the histologic appearance of the endobronchial lesion [6, 7]. Chemotherapy with or without radiotherapy is mandatory for all patients with disseminated disease [8].

* * *

Funding sources: None.

Authors' contribution: AA and YA: Drafting and revising the article. Final approval of the version. Radiological evaluation of the patient. MK and FÇ: Clinical evaluation and management of the patient. DKY: Pathologic evaluation of the patient. The authors state that they have full access to all data in the study and take responsibility for the integrity of the data and the accuracy of the data analysis.

Conflict of interest: The authors declare that they have no conflict of interest.

References

1. Barthwal MS, Deoskar RB, Falleiro JJ, Singh P: Endobronchial non-Hodgkin's lymphoma. *Indian J Chest Dis Allied Sci* 47(2), 117–120 (2005)
2. Hardy K, Nicholson DP, Schaefer RF, Hsu SM: Bilateral endobronchial non-Hodgkin's lymphoma. *South Med J* 88(3), 367–370 (1995)
3. Kaira K, Ishizuka T, Tanaka H, Tanaka Y, Ishizuka T, Yanagitani N, Sunaga N, Hisada T, Mori M: B-cell non-Hodgkin's lymphoma presenting as an endobronchial polypoid mass. *J Thorac Oncol* 3(5), 530–531 (2008)
4. Kilgore TL, Chasen MH: Endobronchial non-Hodgkin's lymphoma. *Chest* 84(1), 58–61 (1983)
5. Hardavella G, Thalassinou N, Anastasiou N: Primary endobronchial non-Hodgkin's lymphoma in an 80-year-old patient with prostate cancer. *Interact Cardiovasc Thorac Surg* 9(4), 739–740 (2009)
6. Solomonov A, Zuckerman T, Goralnik L, Ben-Arieh Y, Rowe JM, Yigla M: Non-Hodgkin's lymphoma presenting as an endobronchial tumor: report of eight cases and literature review. *Am J Hematol* 83(5), 416–419 (2008)
7. Rose RM, Grigas D, Strattemeir E, Harris NL, Linggood RM: Endobronchial involvement with non-Hodgkin's lymphoma. A clinical-radiologic analysis. *Cancer* 57(9), 1750–1755 (1986)
8. Eng J, Sabanathan S: Endobronchial non-Hodgkin's lymphoma. *J Cardiovasc Surg (Torino)* 34(4), 351–354 (1993)